MALT LYMPHOMAS IN PRIMARY SJÖGREN'S SYNDROME

M. Panchovska-Mocheva

Medical University – Plovdiv

Abstract. *Sjögren's syndrome is a systemic autoimmune disease involving the exocrine glands. In the course of the disease, lymphoproliferative disorders are frequent in parallel with the systemic manifestations. The risk of developing lymphomas in patients with Sjögren's syndrome is increased up to 44 times compared to the rest of the population. Among them, MALT lymphomas, which have an indolent course, occupy a special place. Genetic factors, immune processes, and chronic inflammation play a role in the basis of the malignant transformation of the disease, especially the infection with Helicobacter pylori.*

Key words: *Sjögren's syndrome, lymphoproliferative disorders, MALT lymphomas*

MALT (Mucosa-Associated Lymphoid Tissue) lymphomas are extranodal marginal zone lymphomas associated with the mucosal MALT. MALTomas may arise in any organ in which there is chronic persistent inflammation with the development of lymphatic tissue. The most frequently affected are the stomach, salivary glands, and thyroid gland, i.e., organs in which lymphatic tissue appears due to chronic persistent inflammation. The main reason for the development of MALT lymphomas and autoreactive lymphatic tissue is the chronic autoimmune or inflammatory process: Helicobacter pylori infection in the stomach or autoimmune Hashimoto's thyroiditis in the thyroid gland. Prolonged stimulation of T-cells leads to activation of B-cells with intense multiple division, in which DNA fragments are formed with a possibility of subsequent development of lymphomas [1, 2, 3].

Sjögren's syndrome is a systemic autoimmune disease of unknown etiology, characterized by the development of a chronic autoimmune process in the exocrine glands, with the development of parenchymal sialadenitis, xerostomia, and keratoconjunctivitis sicca. Patients with Sjögren's syndrome frequently develop non-Hodgkin's lymphoma (NHL) during the first 10 years of the disease.

A specific morphological finding is the lymphoepithelial lesion in 85 to 100% of patients, found in the major salivary glands. The biopsy of minor salivary glands from the lower lip, introduced in 1966 by Calman HI, Reifman S, Cifarelli PS et al., and the data on focal lymphohistiocytic infiltration of the salivary glands, are accepted to objectify their involvement in Sjögren's syndrome (SS).

In some autoimmune diseases, there is an increased risk of developing hemoblastosis:

1. In Sjögren's syndrome, the risk of developing MALT-lymphomas of the salivary glands increases up to 10 times, and the risk of developing diffuse B-type large cell lymphomas increases up to 9 times.

2. In chronic lymphocytic thyroiditis of Hashimoto, the risk of lymphoma of the thyroid gland increases many times, and in celiac disease, it has been proven for lymphoma of the small intestine [4, 5, 6].

Involvement of the major salivary glands is registered in the following diseases:

1 Autoimmune sialadenitis in Sjögren's syndrome;

2. Granulomatous diseases (sarcoidosis, ANCA-associated vasculitis);

3. IgG4-associated sialadenitis;

4. Neuroendocrine disorders in diabetes mellitus, metabolic syndrome;

5. In alcoholic cirrhosis of the liver;

6. Infectious sialadenitis: bacterial purulent parotitis; viral sialadenitis – in hepatitis, HIV; in syphilis, TB and other infections;

7. Iatrogenic: after anesthesia, administration of iodine preparations, etc.

Tumor lesions of the salivary glands are registered in:

I. Lymphoproliferative processes:

1. B-cell lymphomas: MALT lymphoma, diffuse B-type large cell lymphoma, follicular lymphoma;

2. Amyloidosis-AL, multiple myeloma;

3. T-cell lymphomas, T-type lymphoblastic leukemia/lymphoma;

4. Hodgkin's disease.

II. Tumors of epithelial origin – squamous cell carcinoma.

III. Benign epithelial tumors.

IV. Soft tissue tumors.

MALT lymphomas constitute a separate group due to their peculiarities in course and treatment.

The median age of development of MALT lymphomas is 61 years, with a slight female predominance of 1:1.2.

MALT lymphomas account for 2-5% of all B-cell lymphomas.

However, lymphomas in general account for 2-5% of salivary gland neoplasms. It is believed that 20-40% of salivary gland lymphomas are associated with Sjögren's syndrome. The most common primary location of MALT lymphoma, when not associated with the stomach, is as follows:

1. Head and neck – 30%
2. Orbits – 24%
3. Lungs – 12%
4. Skin – 12%
5. Intestines – 8%
6. Thyroid gland – 7%
7. Breasts – 2%
8. Genitourinary system – 1%

As a localized form of lesion, MALT lymphomas are found in 65% of patients. However, in 35% the involvement is disseminated. The bone marrow is involved in 2-20% of patients [7, 8, 9, 10].

Etiology

The following factors are considered to play a role in the development of MALT lymphomas:

1. Helicobacter pylori – MALT lymphoma of the stomach;
2. HCV infection – marginal zone lymphomas, liver lymphomas;
3. Borrelia Burgdorfery – MALT lymphoma of the skin;
4. Campylobacter jejuni – small intestinal lymphomas;
5. Chlamydia psittaci – MALT lymphomas of the orbit;
6. Sjögren's syndrome – MALT lymphoma of the salivary and lacrimal glands, lungs, stomach;
7. Autoimmune thyroiditis – MALT lymphomas of the thyroid gland;
8. Interstitial pneumonitis – MALT lymphomas of the lungs.

The development of MALT lymphomas is associated with chronic autoimmune processes and infections, which form the substrate for the pathological process (Figure 1).

The mechanisms of lymphoproliferation in primary Sjögren's syndrome are determined by the following factors:

1. Development of lymphoepithelial sialadenitis, with the architectonics of lymph nodes (follicle-like structures with germinal centers);
2. B-cells that express a different idiotype of rheumatoid factors (RF);
3. B-cells that express superficial RF in salivary glands;

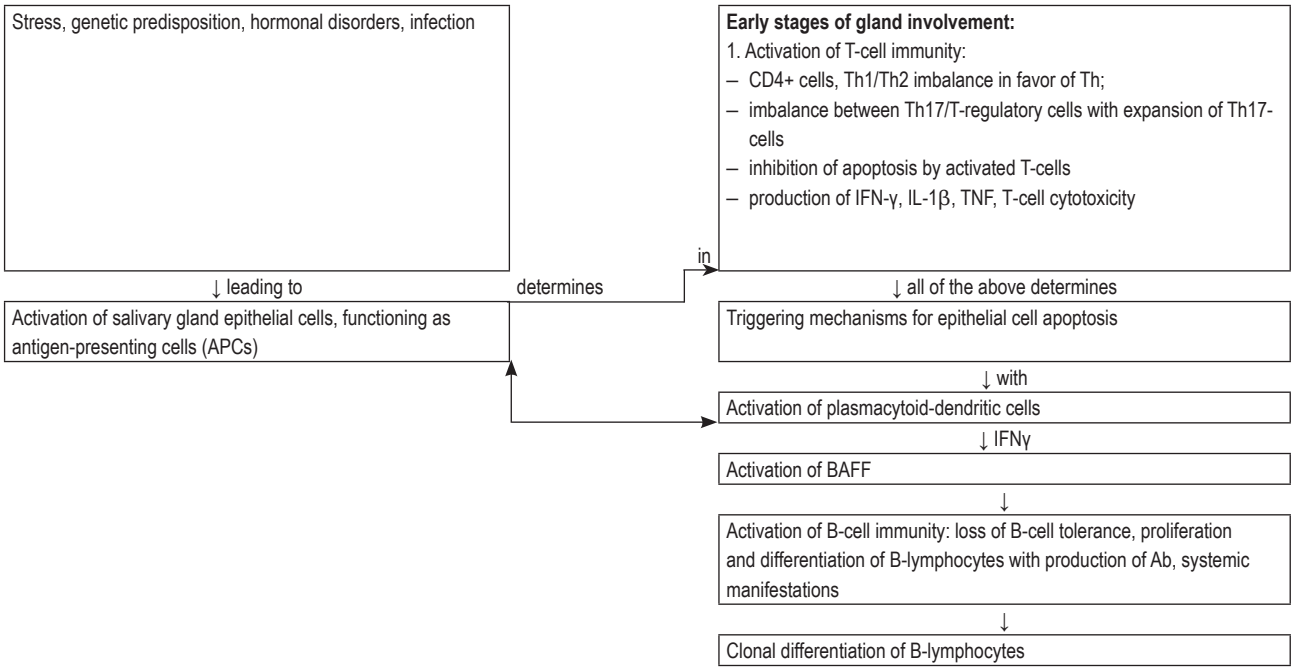

Fig. 1. MALT lymphomas – relationship with chronic autoimmune processes and infections

4. Increased frequency of monoclonal Ig and light chains in urine;

5. Mixed monoclonal cryoglobulinemia;

6. Rearrangement of monoclonal immunoglobulin genes;

7. Mutation of the p53 gene;

8. Chromosomal translocations [14, 18];

9. Increased serum BLyS levels;

10. Transition from polyclonal to oligo- to monoclonal tissue infiltration and development of lymphoma [11, 12, 13, 14, 15].

Table 1 presents the risk of developing hemoblastosis in various rheumatic diseases.

In the diagnostic process of lymphoproliferative disorders and especially MALT lymphomas, a biopsy of the following areas plays an essential role:

1. Parotid salivary gland;

2. Submandibular salivary gland;

3. Transdermal superior periosteal orbitotomy.

The incidence of the types of non-Hodgkin's lymphoma in patients with primary Sjögren's syndrome, show the following distribution:

1. Diffuse B-type large cell lymphoma – 41.2%;

2. Marginal zone lymphomas (MALT) – 48%;

3. Follicular lymphoma – 2.2%;

4. Waldenström' disease – 2.2%;

5. Mantle lymphoma;

6. Plasmacytoma – 4.3%;

7. Chronic lymphocytic leukemia, type B – 2.2%;

8. T-cell non-Hodgkin's lymphomas of salivary glands.

MALT Lymphomas of salivary glands – immunophenotypic characteristics:

1. Tumor cells usually express IgM, less frequently IgA or IgG, and very rarely – light chains;

2. Tumor cells of MALT lymphomas show the following affiliation: CD20+, CD79a+, CD5-, CD10-, CD23-, CD43+, CD5+ is rarely demonstrated;

3. Lymphoma cells express associated CD21 and CD35 marginal zone cells;

4. Presence of light chain restriction is important for the differential diagnosis with benign lymphocytic infiltration [19, 20, 21].

Predictors for the development of lymphoma in primary Sjögren's syndrome include:

1. Significant enlargement of salivary and lacrimal glands;

2. Presence of monoclonal Ig in serum and/or BJ protein in urine;

3. Generalized lymphadenopathy;

4. Recurrent cryoglobulinemic purpura;

5. Polyneuropathy;

6. Ulcero-necrotic vasculitis;

7. Presence of more than 5 foci of lymphocytic infiltration in biopsy of minor salivary glands;

8. Thrombocytopenia below 100 G/l;

9. High levels of IgM;

10. Decreased C4 fraction of the complement;

11. Appearance of a large number of plasma cells in biopsies from minor salivary glands of the lower lip and presence of B-cell clonality in the tissues of minor salivary glands [22-25].

The level of significance of some of the predictors for the development of lymphoproliferative diseases in primary Sjögren's syndrome is presented in Table 2 [26-29].

The role of genetic factors in relation to various mutations is also proven. The frequency of chromosomal translocations and trisomy 3 and 18 in MALT lymphomas of the salivary glands in patients with Sjögren's syndrome is, as follows:

Table 1. Rheumatic diseases and the risk of developing hemopathies [16-18]

	Risk	Factors/Risk	Type of lymphoma
Rheumatoid arthritis	1.9-2.8	1. Inflammatory activity 2. Extra-articular manifestations	Diffuse B-type large cell lymphoma
Felty's syndrome	5-1	1. Granulocytopenia 2. Splenomegaly 3. Methotrexate?	T-cell type leukosis
Primary Sjögren's syndrome	8.7-44	1. Enlargement of parotid glands 2. Mixed monoclonal cryoglobulinemia 3. Lymphadenomegaly	– Marginal zone lymphomas – Diffuse B-type large cell lymphoma – Myeloma
Systemic lupus erythematoda	2.9-10	?	– diffuse B-type large cell lymphoma, myeloma – Hodgkin's disease
Cryoglobulinemic vasculitis	35	?	1. Marginal zone lymphomas 2. Diffuse B-type large cell lymphoma
Systemic scleroderma	0.7-2.5	?	?
Dermatopolymyositis	2-4	In paraneoplastic syndrome?	?

Table 2.

Sign	Significance level
1. Significant enlargement of parotid glands	p < 0.001
2. Generalized lymphadenomegaly	p = 0.002
3. Thrombocytopenia	p = 0.013
4. Mixed monoclonal cryoglobulinemia	p < 0.001
5. More than 5 focus score (in a bioptate of minor salivary glands)	p = 0.011

- t(11; 18)(q21; q22) – 0 до 5%;
- t(14; 18)(q32; q21) – 0 до 16%;
- t(3; 14)(q14,1; q32) – 0;
- + 3 – 55%;
- +18 – 19%.

The authors‘ data for different populations show specific biases in genetic studies [30, 31, 32, 33].

The most common types of lymphomas in primary Sjögren‘s syndrome show belonging to MALT-lymphomas, localized most commonly in parotid glands, and less frequently in the stomach or thyroid gland

In the majority of patients, MALT lymphomas of the stomach are associated with H. pylori infection, which should be actively sought in patients with Sjögren‘s syndrome. Normally, the gastric mucosa does not contain lymphatic tissue. Diffuse lymphoplasmacytic infiltration is present in the lamina propria. Over time, under the influence of antigenic stimulation, B-lymphocytes accumulate genetic aberrations: t(11;18)(q21:q21), t(1;14)(q22:q22) and t(11;18). In 30-50% of cases of differentiated MALT lymphomas, a highly specific translocation, t(11;18), is detected, which is not found in other lymphoma variants. It is believed that this highly specific translocation leads to the appearance of a stable chimeric product (a protein), which has anti-apoptotic effect.

MALT lymphomas, regardless of localization, are characterized by low proliferative activity, and the main pathogenetic mechanism is defective apoptosis.

The translocation t(11;18) is associated with a more aggressive course of MALT lymphomas. It has been shown that this type of translocation makes it difficult to eradicate H. pylori with antibiotics. The translocation t(11;18) is a valuable marker that determines the choice of therapy in patients with MALT lymphoma.

Secondary oncogenic disorders in MALT lymphomas are associated with the oncogenes myc, p53 and p16. The myc oncogene is likely to play a role in the early stages of MALT lymphoma development and is found in both mature cells and aggressive variants.

Specific to MALT lymphomas is the impaired normal activity of an important tumor suppressor gene, the BCL10 gene, which is observed in t(1;14)(q22:q32). As a result of the translocation, the BCL10 gene loses its proapoptotic activity and antitumor potential.

Translocations affect different genes, but they all lead to the activity of NF-κB (nuclear factor–kappa B), which is a key regulator of the expression of genes responsible for the proliferation and apoptosis of lymphocytes. Clinical manifestations of MALT lymphomas of the stomach in the early stages are either absent or do not differ from chronic gastritis or peptic ulcer disease. Most frequently, episodic nocturnal pain in the epigastric region occurs, usually unrelated to food intake, dyspeptic manifestations, burning, belching and vomiting are present.

The diagnosis of MALT lymphomas of the stomach is made through endoscopic examinations. Changes in the gastric mucosa are detected, similar to those in chronic gastritis or peptic ulcer disease: foci of hyperemia, edema, erosions or ulcers [34, 35, 36].

The diagnosis is based on a biopsy of the gastric mucosa, and the histological finding of MALT lymphoma is frequently an unexpected finding. Fibrogastroduodenoscopy with multiple biopsies from each area of the stomach, the duodenum, as well as any suspicious area, is valuable for the diagnosis. Subsequent examinations make it possible to determine the stage of the disease. To detect regional lymphadenopathy and the degree of infiltration of the gastric wall, ultrasound, CAT, as well as important blood tests for β2-microglobulin and LDH levels are performed.

To prove H. pylori, a serological test is performed (if not already proven), a stool test (if not already performed), a computed tomography of the organs in the chest, abdominal cavity, and the lesser pelvis, as well as an aspiration bone marrow biopsy. In addition, immunohistochemical and cytogenetic studies using the FISH method or polymerase chain reaction are applied. The place of positron emission tomography in MALT lymphomas of the stomach is controversial and does not have great clinical significance, which is determined by the indolent course of the disease.

The differential diagnosis between gastric MALT lymphomas and H. pylori-associated gastritis is difficult. The cellular composition of extranodal marginal zone lymphomas shows a diverse tumor substrate. It contains centrocyte-like marginal zone cells, monocytoid B-lymphocytes, small lymphocytes, and plasma cells. An important substrate for gastric MALT lymphomas is the presence of centroblast-like or immunoblast-like cells (up to 10% of all cells) [35, 36].

Extranodal marginal zone lymphomas can transform into large cell lymphomas when centroblasts or

immunoblasts begin to predominate in the cellular composition. In these cases, the diagnosis is now transformed into "diffuse B-type cell lymphoma" rather than aggressive MALT lymphoma, and the therapy changes significantly [34].

Specific immunohistochemical markers in MALT lymphoma have not been found. The typical phenotype of tumor cells in non-Hodgkin's lymphomas of the marginal zone is presented as follows: a reaction is reported only with common markers for B-lymphocytes – CD20, CD43, CD79.

Table 3. Immunophenotypic characteristics of B-cell lymphomas

Type of lymphoma	CD5	CD10	CD23	CD43
MALT-lymphoma	-	-	-	+
Small lymphocyte lymphoma	+	-	+	+
Follicular lymphoma	-	-	- / +	-
Mantle cell lymphoma	+	- / +	-	+

Staging of gastric MALT lymphomas is based on a system developed by the International Extranodal Lymphoma Study Group (IELSG) specifically for gastrointestinal lymphomas. According to this classification, there are three stages of the disease:

Classification

Stage I – the process is localized in the gastrointestinal tract.

I 1 stage – the process is limited to the mucosa ± submucosal layer;

I 2 stage – the process extends into the muscle layer, subserous or serous;

Stage II – in addition to the stomach, the process involves the abdominal lymph nodes and neighboring organs;

Stage II 1 – paragastric lymph nodes are involved;

Stage II 2 – distant lymph nodes are affected (mesenteric, para-aortic, para-caval, pelvic);

Stage III – penetration into neighboring organs and tissues;

Stage IV – diffuse or disseminated involvement of one or more extranodal organs or involvement of the gastrointestinal tract, with involvement of the supradiaphragmatic lymph nodes.

Evidence for the leading role of H. pylori in the etiopathogenesis of MALT lymphomas is the regression in 70-80% of patients under the influence of anti-helicobacter therapy, i.e. eradication of H. pylori. Gastric MALT lymphoma is the only non-Hodgkin's lymphoma tumor in which regression is possible without specific antitumor treatment [37,38,39]

Eradication is not achieved in 20-30% of patients with gastric MALT lymphomas. In these cases, surgical treatment, radiotherapy or therapy with cytostatics is indicated due to the risk of transition to aggressive forms of the disease. In about 10% of cases, gastric MALT lymphomas develop in the absence of H. pylori.

MALT lymphomas represent a special group of tumors that have a specific morphological picture and insufficiently studied clinical manifestations. H. pylori infection should always be considered in treatment regimens.

Immunogenetic studies in recent years have found a link between a certain gene polymorphism with Sjögren's syndrome and its complication, the MALT lymphoma. More and more data confirm the relationship between non-HLA genetic markers with a predisposition to both diseases.

Gene typing and polymorphism of the IRF5, STAT4, TNFAIP3 genes prove the following: polymorphism RF7574865 of the STAT4 gene, RS6920220, polymorphism RS 2230926 of the TNFAIP3 gene are associated with the risk of developing Sjögren's syndrome. The risk is increased for the development of its severe complication, the MALT lymphoma, as well as leukopenia. The TNFAIP3 gene encodes the A20 protein, an enzyme with activity that plays an important role in the regulation of inflammation in the NF-κB signaling pathway. A20 is contained in low concentrations in most cells, but is rapidly induced after NF-κB activation and acts as a negative regulator of inflammation and apoptosis. In mouse models, A20 is important for normal development: in experimental models, mice with A20 deficiency die due to multiorgan inflammation and cachexia [32, 34, 37].

Библиография / References:

1. Thieblemont C, Bertoni F, Copie-Bergman C, et al. Chronic inflammation and extra-nodal marginal-zone lymphomas of MALT-type. Semin Cancer Biol. 2014;24:33–42.
2. Vazquez A, Khan MN, Sanghvi S, et al. Extranodal marginal zone lymphoma of mucosa-associated lymphoid tissue of the salivary glands: a population-based study from 1994 to 2009. Head Neck. 2015;37(1):18–22.
3. Ekstrom Smedby K, Vajdic CM, Falster M, et al. Autoimmune disorders and risk of non-Hodgkin lymphoma subtypes: a pooled analysis within the InterLymph Consortium. Blood. 2008;111(8):4029–38.
4. Bende RJ, van Maldegem F, van Noesel CJ. Chronic inflammatory disease, lymphoid tissue neogenesis and ex-

tranodal marginal zone B-cell lymphomas. Haematologica. 2009;94(8):1109–23.
5. Jackson AE, Mian M, Kalpadakis C, et al. Extranodal marginal zone lymphoma of mucosa-associated lymphoid tissue of the salivary glands: a multicenter, international experience of 248 patients (IELSG 41). Oncologist. 2015;20(10):1149–53.
6. Isaacson PG. Mucosa-associated lymphoid tissue lymphoma. Semin Hematol. 1999;36(2):139–47.
7. Khalil MO, Morton LM, Devesa SS, et al. Incidence of marginal zone lymphoma in the United States, 2001-2009 with a focus on primary anatomic site. Br J Haematol. 2014;165(1):67–77.
8. Kang LY, Ho SP, Chou YP. Primary thymic mucosa-associated lymphoid tissue lymphoma with multiple thin walled lung cysts: case report and literature review. Chin J Cancer Res. 2013;25(3):354–7.
9. Shimizu K, Ishii G, Nagai K, et al. Extranodal marginal zone B-cell lymphoma of mucosa-associated lymphoid tissue (MALT lymphoma) in the thymus: report of four cases. Jpn J Clin Oncol. 2005;35(7):412–6.
10. Derringer GA, Thompson LD, Frommelt RA, et al. Malignant lymphoma of the thyroid gland: a clinicopathologic study of 108 cases. Am J Surg Pathol. 2000;24(5): 623–39.
11. Liang Y, Yang Z, Qin B, Zhong R. Primary Sjögren's syndrome and malignancy risk: a systematic review and meta-analysis. Ann Rheum Dis 2014; 73: 1151-6. https://doi.org/10.1136/annrheumdis-2013-203305
12. Ekstrom K, Vajdic CM, Falster M et al. Autoimmune disorders and risk of non-Hodgkin lymphoma subtypes: a pooled analysis within the InterLymph Consortium. Blood 2008; 111: 4029-38. https://doi.org/10.1182/blood-2007-10-119974
13. Nocturne G, Mariette X. Sjögren Syndrome-associated lymphomas: an update on pathogenesis and management. Br J Haematol 2015; 168: 317-27. https://doi.org/10.1111/bjh.13192
14. Hernández-Molina G, Kostov B, Brito-zerón P et al. Characterization and outcomes of 414 patients with primary SS who developed hematological malignancies. Rheumatology (Oxford) 2022 Apr 6. https://doi.org/10.1093/rheumatology/keac205
15. Kang J, Kim H, Kim J, et al. Risk of malignancy in Korean patients with primary Sjögren's syndrome. Int J Rheum Dis 2020; 23: 1240-7. https://doi.org/10.1111/1756-185x.13927
16. Retamozo S, Acar-Denizli N, Horváth IF et al. Influence of the age at diagnosis in the disease expression of primary Sjögren's syndrome. Analysis of 12,753 patients from the Sjögren Big Data Consortium. Clin Exp Rheumatol 2021; 39 (Suppl. 133): S166-74. https://doi.org/10.55563/clinexprheumatol/egnd1i
17. Björk A, Mofors J, Wahren-Herlenius M. Environmental factors in the pathogenesis of primary Sjögren's syndrome. J Intern Med 2020; 287: 475-92. https://doi.org/10.1111/joim.13032
18. Brito-Zeron P, Acar-Denizli N, NG W-F et al. How immunological profile drives clinical phenotype of primary Sjögren's syndrome at diagnosis: analysis of 10,500 patients (Sjögren Big Data Project). Clin Exp Rheumatol 2018; 36 (Suppl. 112): S102-12.
19. Brito-Zeron P, Retamozo S, Ramos-Casals M. Phenotyping Sjögren's syndrome: towards a personalised management of the disease. Clin Exp Rheumatol 2018; 36 Suppl. 112):198-209.
20. Valim V, Secco A, De Olveira FR, et al. Parotid gland swelling in primary Sjögren's syndrome: activity and other sialadenosis causes. Rheumatology (Oxford) 2022; 61: 2987-92. https://doi.org/10.1093/rheumatology/keab816
21. Vasaitis L, Nordmark G, Theander E et al. Comparison of patients with and without pre-existing lymphoma at diagnosis of primary Sjögren's syndrome. Scand J Rheumatol 2019; 48: 207-12. https://doi.org/10.1080/03009742.2018.1523456
22. Tomi A-L, Belkhir R, Nocturne G, et al. Brief report: Monoclonal gammopathy and risk of lymphoma and multiple myeloma in patients with primary Sjögren's syndrome. Arthritis Rheumatol 2016; 68: 1245-50. https://doi.org/10.1002/art.39534
23. Retamozo S, Brito-Zerón P, Ramos-Casals M. Prognostic markers of lymphoma development in primary Sjögren syndrome. Lupus 2019; 28: 923-36. https://doi.org/10.1177/0961203319857132
24. Brito-Zeron P, Ramos-Casals M, Nardi N, et al. Circulating monoclonal immunoglobulins in Sjögren syndrome. Medicine (Baltimore) 2005; 84: 90-7. https://doi.org/10.1097/01.md.0000157398.37679.47
25. Talal N, Bunim JJ. The development of malignant lymphoma in the course of Sjögren's syndrome. Am J Med 1964; 36: 529-40. https://doi.org/10.1016/0002-9343(64)90101-9
26. Retamozo S, Gheitasi H, Quartuccio L, et al. Cryoglobulinaemic vasculitis at diagnosis predicts mortality in primary Sjögren syndrome: analysis of 515 patients. Rheumatology (Oxford) 2016; 55: 1443-51. https://doi.org/10.1093/rheumatology/kew194
27. Quartuccio L, Baldini C, Priori R et al. Cryoglobulinemia in Sjögren syndrome: a disease subset that links higher systemic disease activity, autoimmunity, and local B cell proliferation in mucosa-associated lymphoid tissue. J Rheumatol 2017; 44: 1179- 83. https://doi.org/10.3899/jrheum.161465
28. Brito-Zeron P, Ramos-Casals M, Bove A, et al. Predicting adverse outcomes in primary Sjögrensyndrome: identification of prognostic factors. Rheumatology (Oxford) 2007; 46: 1359-62.https://doi.org/10.1093/rheumatology/kem079
29. Nocturne G, Virone A, NG W-F, et al. Rheumatoid factor and disease activity are independent predictors of lymphoma in primary Sjögren's syndrome. Arthritis Rheumatol 2016; 68: 977-85. https://doi.org/10.1002/art.39518
30. Anderson LG, Cummings NA, Asofsky R et al. Salivary gland immunoglobulin and rheumatoid factor synthesis in Sjögren's syndrome. Natural history and response to treatmentAm J Med 1972; 53: 456-63. https://doi.org/10.1016/0002-9343(72)90141-6
31. Sisó-Almirall A, Meijer JM, Brito-Zerón P, et al. Practical guidelines for the early diagnosis of Sjögren's syndrome in primary healthcare. Clin Exp Rheumatol 2021; 39 (Suppl.

133): S197-205. https://doi.org/10.55563/clinexprheumatol/pal3z7
32. Sugimoto KJ, Asahina M, Shimada A, et al. IgG3 subclass-positive primary thymic MALT lymphoma without trisomy 3 and trisomy 18: report of a case and review of literature. Int J Clin Exp Pathol. 2014;7(12):8980–7.
33. Brito-Zeron P, Acar-Denizli N, Zeher M et al. Influence of geolocation and ethnicity on the phenotypic expression of primary Sjögren's syndrome at diagnosis in 8310 patients: a cross-sectional study from the Big Data Sjögren Project Consortium. Ann Rheum Dis 2017; 76: 1042-50. https://doi.org/10.1136/annrheumdis-2016-209952
34. Zucca E, Bertoni F, Roggero E, Cavalli F. The gastric marginal zone B-cell lymphoma of MALT type. Blood. 2000;96(2):410–9.
35. Pereira MI, Medeiros JA. Role of Helicobacter pylori in gastric mucosaassociated lymphoid tissue lymphomas. World J Gastroenterol. 2014;20(3): 684–98.
36. Asenjo LM, Gisbert JP. Prevalence of Helicobacter pylori infection in gastric MALT lymphoma: a systematic review. Rev Esp Enferm Dig. 2007;99(7):398–404.
37. Parsonnet J, Hansen S, Rodriguez L, et al. Helicobacter pylori infection and gastric lymphoma. N Engl J Med. 1994; 330(18):1267–71.

Постъпил за печат: 24.07.2025 г.

Submitted: 24.07.2025

✉ *Адрес за кореспонденция:*
Проф.д-р Мария Панчовска-Мочева, д.м., мзм
Медицински университет – Пловдив
e-mail: panchovska@abv.bg

✉ *Correspondence address:*
Prof. Dr. Maria Panchovska-Mocheva, Ph.D., M.H.M.
Medical University – Plovdiv
e-mail: panchovska@abv.bg